



CHECK TODAY. SEE TOMORROW

# Diabetic Retinopathy Screening Card

Check for **Red** and White Signs\*. Look at where they are located and how much of the retina is affected – does the retina look normal, abnormal or sight-threatening? \*See other side

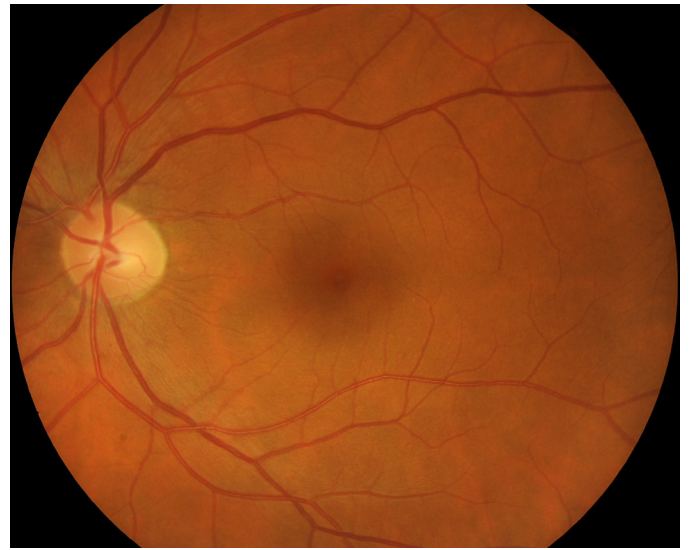## Normal

### Vision

Presenting vision 6/12 or better in each eye

### Retina

No signs of Diabetic Retinopathy



## Routine eye examination

(Indigenous within 12 months,  
Non-Indigenous within 2 years)

## Abnormal

### Vision

Presenting vision worse than 6/12 in either eye or

### Retina

Unable to View Retina or  
Diabetic Retinopathy showing any:

### Red Signs

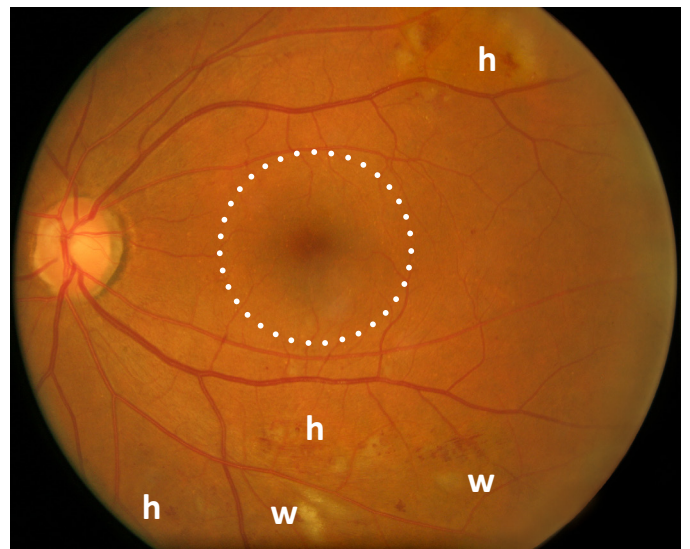
- Haemorrhages (**h**) in less than 4 quadrants
- Venous beading (**v**) in 1 quadrant\*

### White Signs

- Cotton wool spots (**w**)
- Hard exudates (**e**) more than 1 optic disc diameter from macula (as outlined with dots)

## Refer to optometrist or ophthalmologist

(to be seen within 90 days)



## Sight-threatening

### Retina

Severe Diabetic Retinopathy or  
Macular Oedema showing any:

### Red Signs

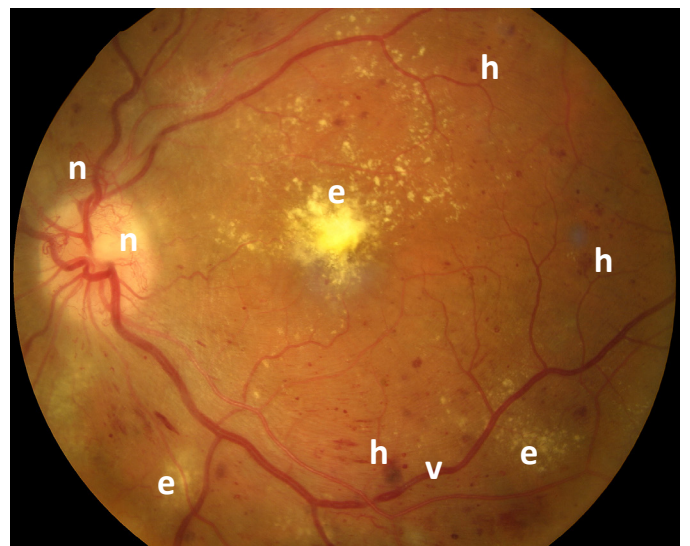
- New blood vessels (**n**) on optic disc or elsewhere
- Venous beading (**v**) in 2 or more quadrants
- Haemorrhages (**h**) in all 4 quadrants
- Intra retinal microvascular abnormalities\*
- Vitreous haemorrhage\*

### White Signs

- Hard exudates (**e**) within 1 optic disc diameter of macula

## Refer urgently to the ophthalmologist

(to be seen within 30 days)

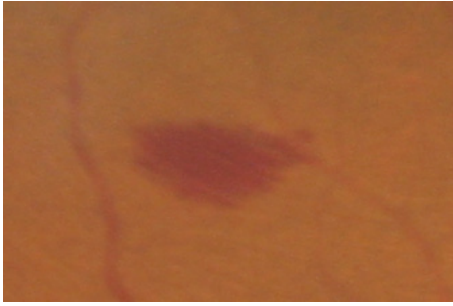



CHECK TODAY, SEE TOMORROW

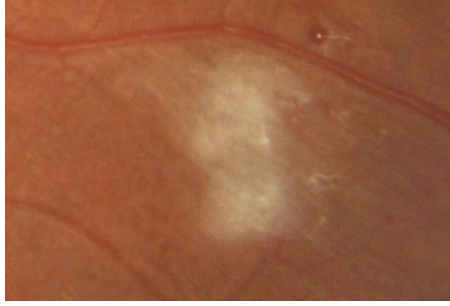
# Diabetic Retinopathy Signs

## Retinopathy Signs - to be seen within 90 days



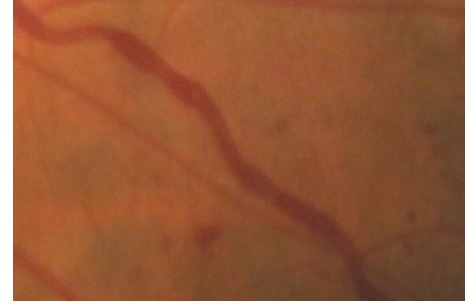### Intraretinal haemorrhages (h)

Haemorrhages are seen as red lesions in the retina and can vary in shape. They can be small red dots, larger blot lesions with round, blurred or irregular edges, or flame shaped. Haemorrhages in all 4 quadrants require urgent referral.



### Cotton wool spots (w)

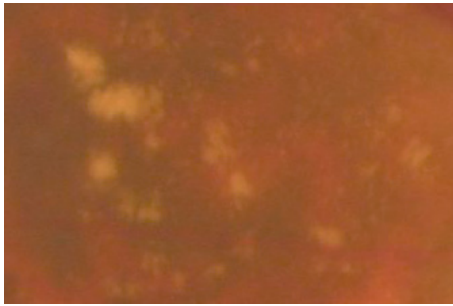
Cotton wool spots appear as grayish/whitish spots with soft, fuzzy edges, giving them a resemblance to a ball of cotton wool. They do not usually appear in clusters like hard exudate.



### Venous beading (v)

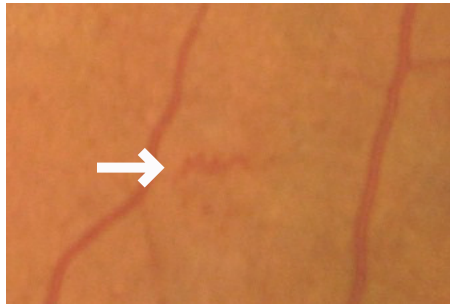
Venous beading has an appearance ranging from slight irregularity of the venule caliber, to a sausage-like dilatation. Venous beading in 2 or more quadrants requires an urgent referral.

## Sight-threatening Retinopathy Signs - to be seen within 30 days



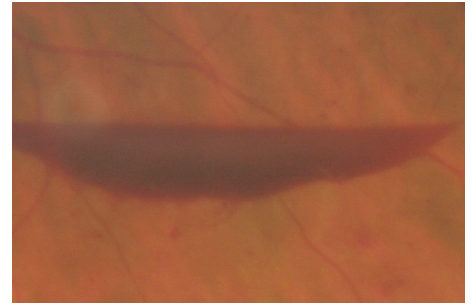
### Hard exudates (e)

Hard exudates are pale yellow, waxy looking lesions in the retina. Where there is evidence of hard exudate within 1 optic disc diameter (1500 microns) of the macula, an urgent referral is required.



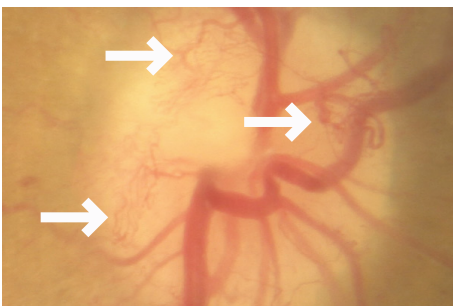
### Intraretinal microvascular abnormalities (irma)

Intraretinal microvascular abnormalities often appear as small red squiggles in areas between major vessels and stand apart from the more regular array and branching of retinal vessels due to their delicate and jagged appearance.



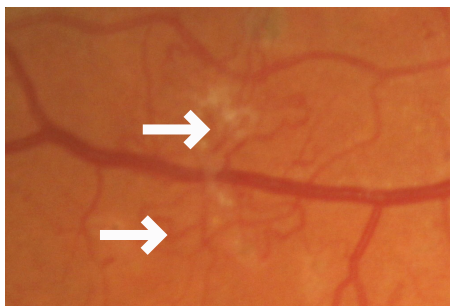
### Vitreous haemorrhage

Small vitreous haemorrhages may appear as dark "floaters" in the vitreous. Large haemorrhages may obscure the retina entirely. These lie under the surface membrane of the retina and may be boat shaped due to the effect of gravity.



### New blood vessels (n)

New vessels can be seen on or around the optic disc, or elsewhere in the retina. The appearance of new vessels can vary, but new vessels always form loops and nets whereas normal retinal vessels never form loops.



**Minim Barreng**  
Indigenous Eye Health  
Melbourne School of Population and Global Health



This card can be downloaded:  
[www.iehu.unimelb.edu.au](http://www.iehu.unimelb.edu.au)

**Free online Retinopathy Grading Course: [drgrading.iehu.unimelb.edu.au](http://drgrading.iehu.unimelb.edu.au)**

