CHECK TODAY, SEE TOMORROW

Eye Care for Aboriginal and Torres Strait Islander People with Diabetes

Acknowledgements:

Indigenous Eye Health (IEH) at The University of Melbourne would like to acknowledge the contribution and guidance of the:

- Ballarat and District Aboriginal Co-Operative (BADAC)
- Budja Budja Aboriginal Co-Operative
- Looma Remote Area Clinic
- Deception Bay Clinic

and community members in these regions in the development of the '**Check Today, See Tomorrow**' resources.

IEH would also like to acknowledge the following for their input:

- Kimberley Aboriginal Medical Services Council (KAMSC)
- Western Australia Country Health Service (WACHS)
- Institute for Urban Indigenous Health (IUIH)
- Queensland Aboriginal and Islander Health Council (QAIHC)
- Victorian Aboriginal Community Controlled Health Organisation (VACCHO)
- Victorian Aboriginal Health Service (VAHS)
- Australian College of Optometry (ACO)
- National Aboriginal Community Controlled Health Organisation (NACCHO)
- Diabetes Australia
- Lions Outback Vision

Support for this project was provided by private donors, The Australian Government Department of Health, The Ian Potter Foundation, and The Aspen Foundation.

The artwork for this project was created through a series of community art workshops held in Looma, Western Australia, Deception Bay, Queensland and Ballarat, Victoria. Gilimbaa Creative Agency and Indigenous Hip Hop Projects (IHHP) have supported the development of the resources.

THE UNIVERSITY OF MELBOURNE

Minum Barreng

Australian Government Department of Health

Ballarat and District Aboriginal Co-operative Ltd

Budja Budja Aboriginal Cooperative

Government of Western Australia WA Country Health Service

IUIH Institute for urban indigenous health

"As I grow older, I want to SEE TOMORROW"

Welcome

Diabetes is a major cause of vision loss and blindness for Aboriginal and Torres Strait Islander people, however up to 98% of blindness is preventable.

By advising and supporting Aboriginal and Torres Strait Islander people with diabetes to get an eye check YEARLY, you can help reduce their risk of vision loss and blindness.

Using The Flipchart

This flipchart has been produced by Indigenous Eye Health (IEH) at The University of Melbourne, as part of a broader program of activities within the *Roadmap to Close the Gap for Vision* which aims to improve eye health outcomes for Aboriginal and Torres Strait Islander people. This flipchart aims to share important information with Aboriginal and Torres Strait Islander people with diabetes on the seriousness of diabetes related eye complications, particularly diabetic retinopathy.

The flipchart covers areas such as:

- The eye
- What is diabetic retinopathy?
- Who can develop diabetic retinopathy?
- Importance of a YEARLY eye check for people with diabetes
- What happens during an eye check
- Treatment options for diabetic retinopathy
- Preventing vision loss from diabetic retinopathy
- Key messages and further support.

It also includes additional screening tools for diabetic retinopathy.

Supporting Aboriginal And Torres Strait Islander People With Diabetes Eye Care

1. **Early Detection and YEARLY Eye Checks**
   Many people with diabetes, including primary care providers, are unaware of the critical need for Aboriginal and Torres Strait Islander people to have a YEARLY eye check. Yearly eye checks are key to detecting problems early even before symptoms start to show.

2. **Education and Support for Self-Management**
   Educating and supporting people with diabetes on the risk factors for developing eye disease (including high blood sugars, blood pressure, cholesterol) is important for preventing vision loss and blindness.

3. **Referral Pathways**
   Providing information about eye care pathways will help Aboriginal and Torres Strait Islander people get to the next step – for further assessment with an eye specialist optometrist and/or an ophthalmologist (specialist eye doctor). Most optometry services are covered by a Medicare rebate.

4. **Timely Treatment**
   Once diabetic retinopathy is detected, supporting people on the importance of following treatment as directed by an eye specialist can prevent vision loss from diabetes.

This flipchart is intended to be used with other **'Check Today, See Tomorrow'** resources in the *Roadmap to Close the Gap for Vision toolkit*.

For more information, please visit: *www.iehu.unimelb.edu.au*

The Eye

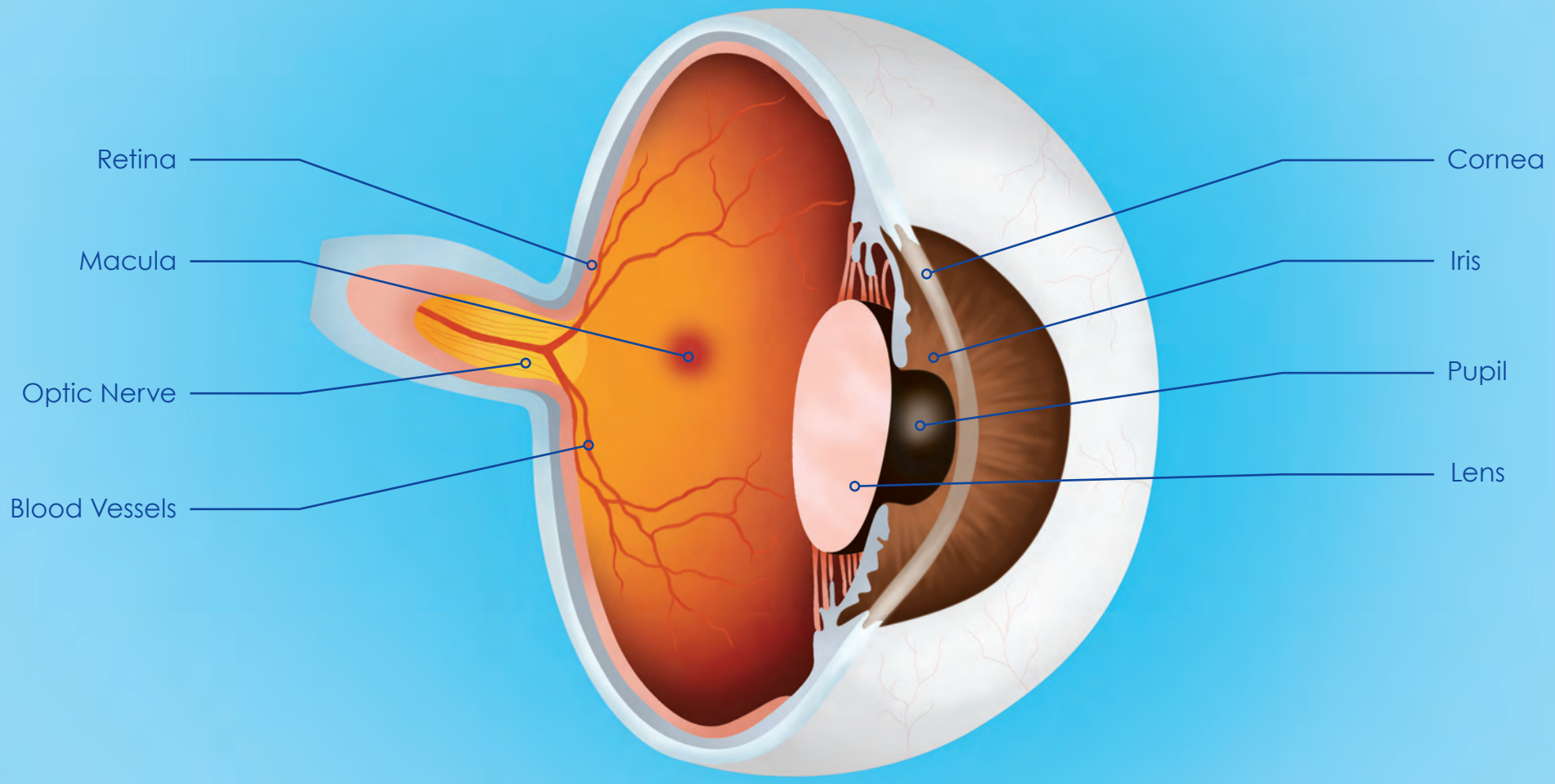
Retina
Macula
Optic Nerve
Blood Vessels
Cornea
Iris
Pupil
Lens

The Eye

The eye has several key components:

Cornea	is the clear outer part at the front of the eye. Helps to focus light through the pupil to the retina.
Iris	is the coloured part of the eye. Regulates the amount of light entering the eye.
Pupil	is the opening at the centre of the iris. The iris adjusts the size of the pupil and controls the amount of light that can enter the eye.
Lens	is a clear part of the eye behind the iris that helps to focus light, or an image, on the retina.
Vitreous gel	is a transparent, colourless gel that fills the eyeball between the lens and the retina.
Retina	appears as a red/orange layer of tissue at the back of the eye. It is the light-sensitive tissue at the back of the eye that signals vision to the brain.
Macula	is the central area of the retina. This part of the retina is responsible for fine, detailed vision.
Blood Vessels	are made up of arteries and veins visible on the retina. They allow blood to maintain the function of the retina.
Optic nerve	appears as a round nerve in the retina. It provides messages from the retina to the brain and is responsible for the blind spot.

What Is Diabetic Retinopathy?

Diabetes can damage the tiny blood vessels in the retina at the back of your eye causing an eye disease, called diabetic retinopathy, to develop.

There are two main stages of diabetic retinopathy:

'Early stage' of diabetic retinopathy

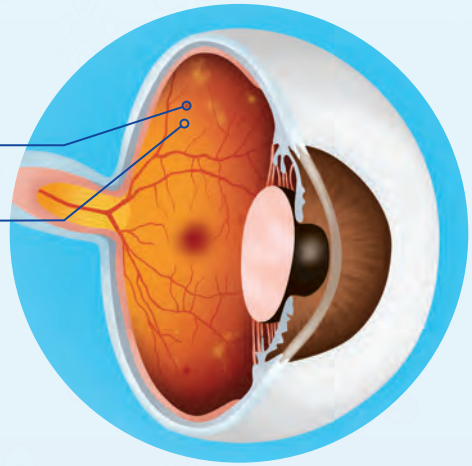

A closer look at the damaged retina during an eye check

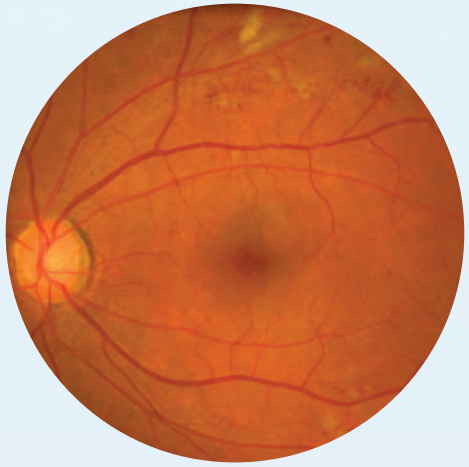

'Sight-threatening stage' of diabetic retinopathy

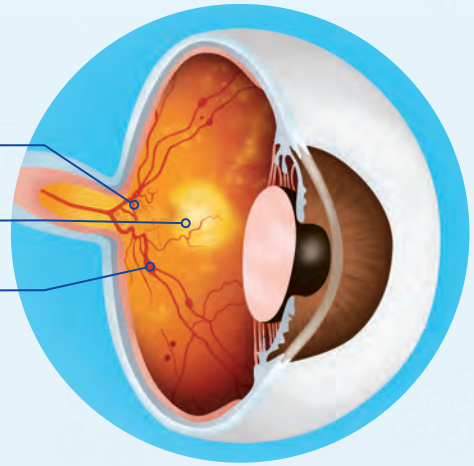

A closer look at the damaged retina during an eye check



What Is Diabetic Retinopathy?

A healthy retina is needed for good vision.

- Diabetes can damage the tiny blood vessels in the retina at the back of your eye causing an eye disease called diabetic retinopathy to develop.
- These blood vessels can swell, bleed (haemorrhage) or leak fats and fluid into the retina causing fuzzy white spots (cotton wool spots) to develop. This **'early stage'** of diabetic retinopathy (non-proliferative) is the most common stage: many people with diabetes have it.
- If blood vessels in the macula in the central part of your retina bleed or leak fluid, blurry vision may result. This is called **macular oedema**.
- If diabetic retinopathy progresses to a **'sight-threatening stage'** (proliferative), new abnormal blood vessels develop (neovascularisation) and leak blood (haemorrhages) into your retina, leading to severe vision loss.

Who Can Develop Diabetic Retinopathy?

Everyone with type 1 and type 2 diabetes is at risk of developing diabetic retinopathy.

Who Can Develop Diabetic Retinopathy?

- Everyone with type 1 and type 2 diabetes is at risk of developing diabetic retinopathy.
- The longer you have diabetes, the more likely it is that you will develop diabetic retinopathy.
- If blood sugar (glucose) levels, blood pressure and blood lipids (cholesterol) are not well controlled the risk of developing diabetic retinopathy is higher.

How Can Diabetic Retinopathy Cause Vision Loss?

Diabetic retinopathy damages your eyes even before you see changes in your vision.

Normal Vision

If left untreated, diabetic retinopathy can cause severe vision loss.

Vision with 'spots' from bleeding in the retina

How Can Diabetic Retinopathy Cause Vision Loss?

Diabetic retinopathy damages your eyes even before you see changes in your vision.

There are no signs or symptoms in the early stages of diabetic retinopathy.

Vision loss from diabetic retinopathy usually develops from damage in the retina including:

- build up of tissue fluid at macula (macular oedema)
- changes to and leaky blood vessels
- bleeding
- new abnormal, blood vessels
- detachment of the retina.

If diabetic retinopathy progresses to a sight-threatening stage, its signs or symptoms may include:

- changes in near or distance vision
- blurred vision
- seeing spots or floaters in your vision
- blank or dark areas in your vision.

If you notice any of these 'sight-threatening' signs or symptoms you should see your local clinic immediately.

How Is Diabetic Retinopathy Detected?

The only way to detect diabetic retinopathy is through an eye check or a full eye examination.
An eye check will detect the early signs of any damage to your retina and help you before your vision is affected.

The eye check for people with diabetes must include:

a. A test of how well you see (Visual Acuity)



b. A look at the back of your eyes (Retinal Examination)

a photograph taken with a retinal camera

OR

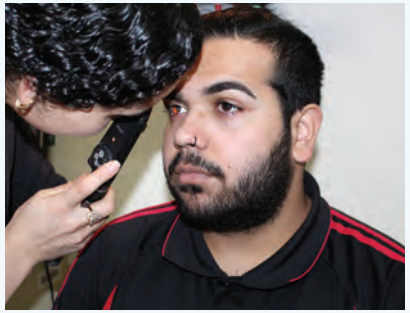

with an ophthalmoscope

with a slit-lamp

All Aboriginal and Torres Strait Islander people with diabetes should have an eye check YEARLY to detect any changes in their retina.

How Is Diabetic Retinopathy Detected?

The only way to detect diabetic retinopathy is through an eye check or a full eye examination.

An eye check will detect the early signs of any damage to your retina and help you before your vision is affected.

An eye check can be carried out at your clinic by clinic staff e.g. health worker, nurse, doctor or someone who has been appropriately trained.

The eye check for people with diabetes must include:



a. A test of how well you see (Visual Acuity)

A test to read an eye chart to measure how well you see at different distances.

b. A look at the back of your eyes (Retinal Examination)

- a photograph taken of the back of the eye, or
- a retinal examination using ophthalmoscopy (slit-lamp or ophthalmoscope) usually by an eye specialist (optometrist or ophthalmologist).

To see your retina properly drops may be put in your eye to dilate (widen) your pupil.

An eye check can also detect other changes and problems with your eyes and vision.

When you are first diagnosed with diabetes you should have an eye check and then have an eye check every year after that.

All Aboriginal and Torres Strait Islander people with diabetes should have a YEARLY eye check to detect any changes in their retina.

What Happens After An Eye Check?

The results of your eye check will determine what happens next:

Normal vision and normal retina.

It is important to continue to have an eye check every year and to manage your diabetes.

Vision change or eye symptoms.

You will be referred for further assessment with an eye specialist.

Diabetic retinopathy found.

You will be referred for further assessment with an eye specialist.

Other eye conditions found.

People with diabetes are at increased risk of developing other eye conditions such as cataract (clouding of lens)– you will be referred for further assessment and treatment with an eye specialist.

What Happens After An Eye Check?

The results of your eye check will determine what happens next:

Normal retina and normal vision found	if no damage or changes to your retina or vision are detected it is important to have an eye check every year and to control your blood sugar, blood pressure and blood lipids (cholesterol) levels.
Vision change or eye symptoms are found	you will be referred for further assessment with an eye specialist who may prescribe eye glasses if required.
Diabetic retinopathy found	will be referred for further assessment to an eye specialist to discuss if treatment is needed. If diabetic retinopathy is found early and treated, there is a better chance of preventing vision loss and blindness.
Other eye conditions found	other conditions such as cataract (clouding of lens in eye) may be found. Your will be referred to an eye specialist for further assessment.

Eye Specialist:

Optometrist	**Health professional who assesses eye health and visual problems including the prescription and provision of eye glasses.**
Ophthalmologist	**Specialist eye doctor who manages and treats eye disease including eye surgery.**

How is Diabetic Retinopathy Treated?

Treatment will depend on what the ophthalmologist (eye specialist doctor) sees in your eyes.

Treatment options may include:

Laser treatment

uses a special beam of light to treat the damaged blood vessels inside your eye

Eye injection

medication is given by injections into your eye to slow blood vessel leakage

Eye surgery

vitreous gel and blood removed from your retina so light can focus on retina again

Laser treatment for diabetic retinopathy

Retina after laser treatment

If left untreated, diabetic retinopathy can cause vision loss or blindness.

How Is Diabetic Retinopathy Treated?

If you develop diabetic retinopathy, your ophthalmologist (specialist eye doctor) will know when and how to treat the damage to your eyes.

Treatment options may include:

Laser treatment (photocoagulation)	Eye injections ('intravitreal anti-VEGF' medication)	Eye Surgery (Vitrectomy)
• Uses special beam of light to seal off weak or leaking blood vessels in your retina to stop bleeding and reduce swelling of the retina. • Focal laser treatment for macular oedema. • Pan retinal photocoagulation (PRP) for sight-threatening (proliferative) retinopathy.	• The medication is given by injections in your eye. • It is performed under local anesthetic. • This helps to slow blood vessel leakage and reduce swelling of the macula. • Stops new blood vessels growing. • Needs to be repeated every few months depending on how your eye responds.	• It is performed in hospital under anaesthetic. • May be needed if bleeding from the retina into the eyeball is causing cloudy vision or if scarring has occurred. • The vitreous gel, blood and scar tissues are removed from the back of your eye. • This will allow light to focus on the retina again.

If left untreated, diabetic retinopathy can cause vision loss or blindness.

How Do I Prevent Vision Loss From Diabetic Retinopathy?

Early Detection

Control Blood Sugar Levels

Control blood pressure and cholesterol levels

Healthy Eating

Physical activity/ Healthy weight

Take medications as prescribed

Quit smoking

Good diabetes management is essential to prevent vision loss from diabetic retinopathy.



How Do I Prevent Vision Loss From Diabetic Retinopathy?

There are several factors that can influence its development and/or progression:

- **Early detection:** a YEARLY eye check is key to detecting problems early even before symptoms start to show, to prevent vision loss from diabetic retinopathy. Vision loss from diabetes is not normal and it can be prevented by detecting damage early. Notify your clinic immediately if you notice any changes in your vision.
- **Control blood sugar levels:** keeping blood sugars well controlled reduces the risk of vision loss from diabetes.
- **Control blood pressure and cholesterol:** high blood pressure has been shown to make eye problems worse.
- **Healthy eating** is an important part of diabetes management.
- **Add more physical activity to your daily activities**
- **Take medications as prescribed by your doctor**
- **Quit smoking**

Good diabetes management is essential to prevent vision loss from diabetic retinopathy.

Further Information And Support

Other components within the 'Check Today, See Tomorrow' resource package:

- **Poster series and postcards –** for display in waiting rooms and other community settings
- **Brochure –** for display in waiting rooms and for distribution to people with diabetes
- **Digital resources –** includes personal stories, music videos, community service announcements (CSAs) on diabetes and eye health messages.

Diabetic retinopathy screening support tools for health professionals included in this flipchart:

- **'Eye Exam' component of the MBS Item 715 Adult Health Check -** contains 4 key steps to conduct eye exam component
- **Visual Acuity Chart**
- **Diabetes Retinopathy Screening Card –** referral criteria for diabetic retinopathy

Additional support tools:

- **Free Online Diabetic Retinopathy Grading course** *www.iehu.unimelb.edu.au*

For additional information regarding the '***Check Today, See Tomorrow***' resource package, or **to order additional resources** please visit *www.iehu.unimelb.edu.au*

Eye Exam for Adult Health Check

MBS Item 715 (Health Assessment for Aboriginal and Torres Strait Islander peoples) now includes a mandatory basic eye check. A basic eye check can compose of the following

STEP 1: History

- Ask about problems or difficulties with vision or eyes
  Consider 'sore or watery eye' as possible symptom of trichiasis
- Ask about problems with glasses or contact lenses
- Ask "can you see clearly and comfortably?"
  - *When looking at things up close (eg when held in your hands)?*
  - *When looking at things far away?*
- Ask/check whether the person has diabetes

STEP 2: Vision Test

- Test near vision:
  Test both eyes together, with glasses if normally worn. You can use the test on the back of this card at a comfortable distance
- Test distance vision:
  Test one eye at a time, with glasses if normally worn, for vision using an acuity chart. You can use the test on the back of this card.

STEP 3: Eye examination

- Check eye movements
- Check pupils
- Check the front of the eye
  Lids, lashes, conjunctiva, cornea
  Consider trichiasis, remember the 3 T's – Think, Thumb, Torch
- Check retina for people with diabetes each year:
  Dilated ophthalmoscopy, retinal photography if camera available or refer

STEP 4: Refer

Refer to an optometrist or ophthalmologist if:

- Vision or eye problems including a change in vision
- Reduced vision at near (worse than N8) or distance (worse than 6/12)
- Retinal examination is needed for people with diabetes each year

Optometry Australia | NACCHO | RANZCO | RACGP

When testing for near and distance vision please ensure that glasses or contact lenses (if usually worn) are worn while reading text and that there is suitable lighting in the room.

Near Vision (N8)

Test both eyes together at a comfortable reading distance

Distance Vision (6/12)

Test one eye at a time from a distance of 3m

The above text can be rotated to change symbol sequence by turning page clockwise.

If any trouble reading symbols from either test please refer

Diabetic Retinopathy Screening Card

Check for Red and White Signs*. Look at where they are located and how much of the retina is affected – does the retina look normal, abnormal or sight-threatening?

Normal

Vision
Presenting vision 6/12 or better in each eye

Retina
No signs of Diabetic Retinopathy

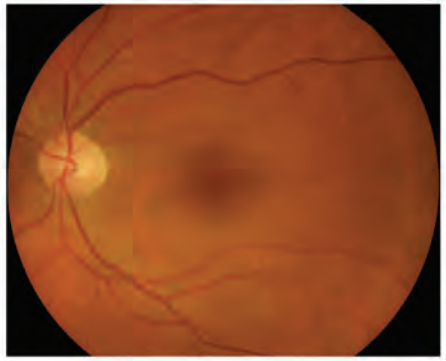

Routine eye examination
(Indigenous within 12 months, Non-Indigenous within 2 years)

Abnormal

Vision
Presenting vision worse than 6/12 in either eye *or*

Retina
Unable to View Retina *or*
Diabetic Retinopathy showing any:

Red Signs
- Haemorrhages **(h)** in less than 4 quadrants
- Venous beading **(v)** in 1 quadrant*

White Signs
- Cotton wool spots **(w)**
- Hard exudates **(e)** more than 1 optic disc diameter from macula (as outlined with dots)

Refer to optometrist or ophthalmologist
(to be seen within 90 days)

Sight-threatening

Retina
Severe Diabetic Retinopathy *or*
Macular Oedema showing any:

Red Signs
- New blood vessels **(n)** on optic disc or elsewhere
- Venous beading **(v)** in 2 or more quadrants
- Haemorrhages **(h)** in all 4 quadrants
- Intra retinal microvascular abnormalities*
- Vitreous haemorrhage*

White Signs
- Hard exudates **(e)** within 1 optic disc diameter of macula

Refer urgently to the ophthalmologist
(to be seen within 30 days)

* See other side

Diabetic Retinopathy Signs

Retinopathy Signs - to be seen within 90 days

Intraretinal haemorrhages (h)
Haemorrhages are seen as red lesions in the retina and can vary in shape.
They can be small red dots, larger blot lesions with round, blurred or irregular edges, or flame shaped.
Haemorrhages in all 4 quadrants require urgent referral.

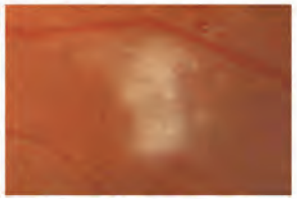

Cotton wool spots (w)
Cotton wool spots appear as grayish/whitish spots with soft, fuzzy edges, giving them a resemblance to a ball of cotton wool. They do not usually appear in clusters like hard exudate.

Venous beading (v)
Venous beading has an appearance ranging from slight irregularity of the venule caliber, to a sausage-like dilatation. Venous beading in 2 or more quadrants requires an urgent referral.

Sight-threatening Retinopathy Signs - to be seen within 30 days

Hard exudates (e)
Hard exudates are pale yellow, waxy looking lesions in the retina.
Where there is evidence of hard exudate within 1 optic disc diameter (1500 microns) of the macula, an urgent referral is required.



Intraretinal microvascular abnormalities (irma)
Intraretinal microvascular abnormalities often appear as small red squiggles in areas between major vessels and stand apart from the more regular array and branching of retinal vessels due to their delicate and jagged appearance.

Vitreous haemorrhage
Small vitreous haemorrhages may appear as dark "floaters" in the vitreous. Large haemorrhages may obscure the retina entirely. These lie under the surface membrane of the retina and may be boat shaped due to the effect of gravity.

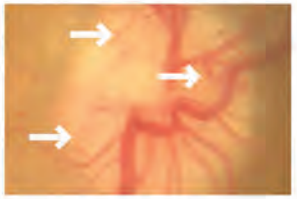

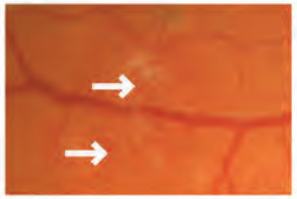

New blood vessels (n)
New vessels can be seen on or around the optic disc, or elsewhere in the retina.
The appearance of new vessels can vary, but new vessels always form loops and nets whereas normal retinal vessels never form loops.

Minum Barreng
Indigenous Eye Health

Melbourne School of Population & Global Health

www.iehu.unimelb.edu.au
This card can be downloaded from this website
01/2015

Free online Retinopathy Grading Course: drgrading.iehu.unimelb.edu.au

More information

For more information about the **'Check Today, See Tomorrow'** resource package, or the **Roadmap to Close the Gap for Vision toolkit** please visit www.iehu.unimelb.edu.au or contact:

Indigenous Eye Health
Level 5, 207 Bouverie Street,
The University of Melbourne,
Parkville, 3010
Tel: (03) 8344 9320
Email: Indigenous-EyeHealth@unimelb.edu.au